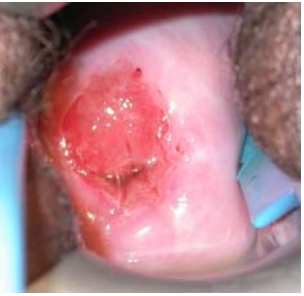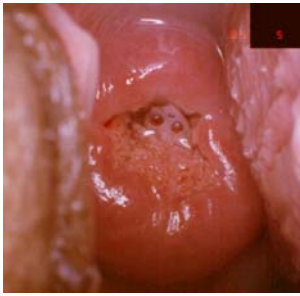


# Asetik Asitle Görsel Muayene (VIA) için Klinik Referans Kartı

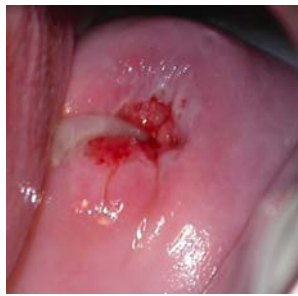## VIA NEGATİF



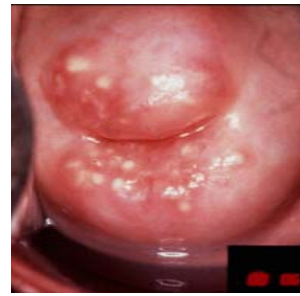Asetowhite belirlenmemiş alan



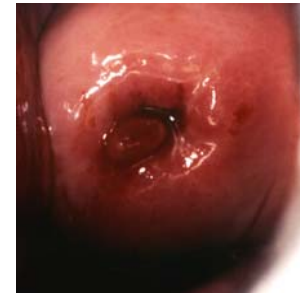Kolumnar epitelde mukusun asetowhite görünümü



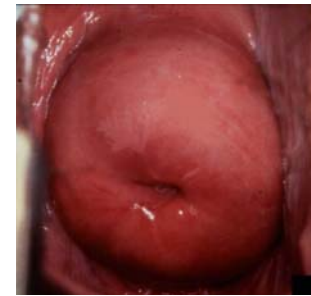Mukus tıkaçı



Naboti kistleri

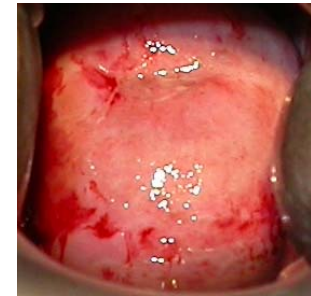
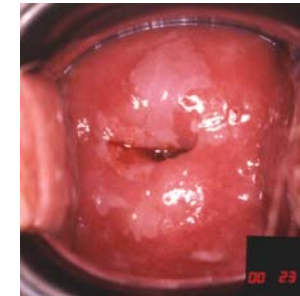
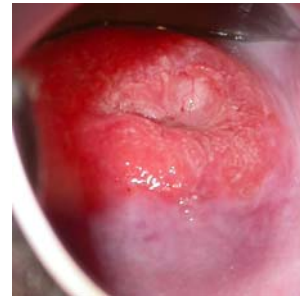
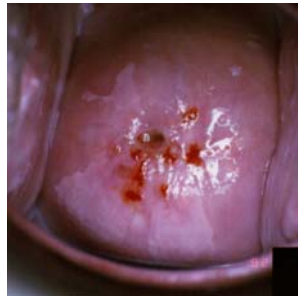
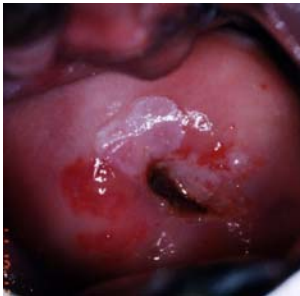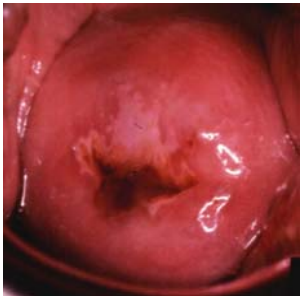Polip



SKB'den uzak asetowhite bölge

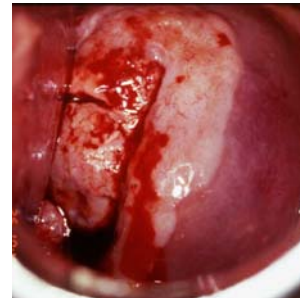
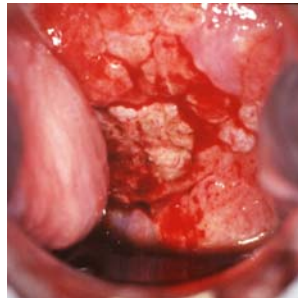
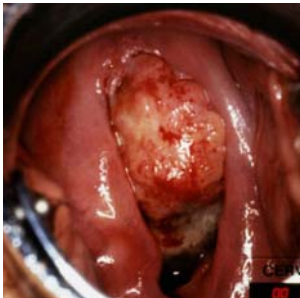
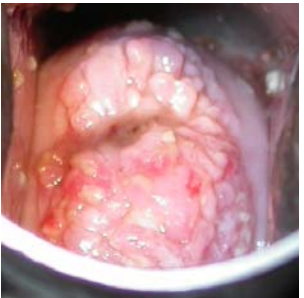## VIA POZİTİF



Serviksin tümünü kaplayan asetowhite alan

-----SKB'de veya servikal os'a yakın iyi belirlenmiş asetowhite lezyonlar-----

## KANSER



SKB: Skuamokolumnar bileşke

Kaynak: R. Sankaranarayanan, Ramani S. Wesley. A practical manual on visual screening for cervical neoplasia (IARC technical publication No 41) Available from: [press@iarc.fr](mailto:press@iarc.fr) (IARC Press)

-----Serviksteki kitlenin asetowhite görünümü-----

Serviksteki kitlenin asetowhite görünümü; kanamaya bağlı kısmen görüntüde bozulmalar

