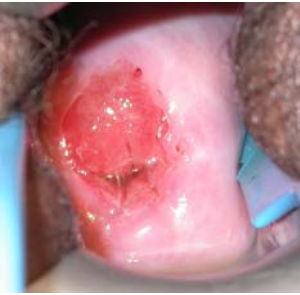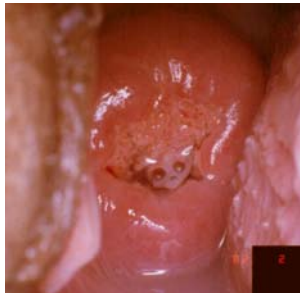


Quick Clinical Reference Chart for Visual Inspection with Acetic Acid (VIA)

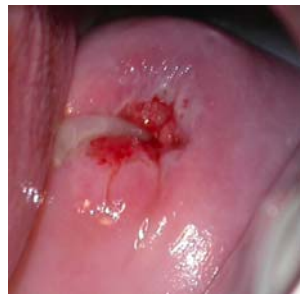VIA NEGATIVE



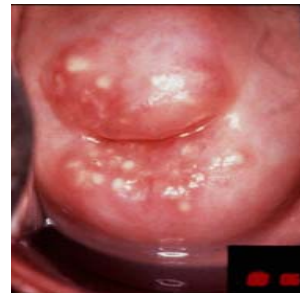No definite acetowhite area



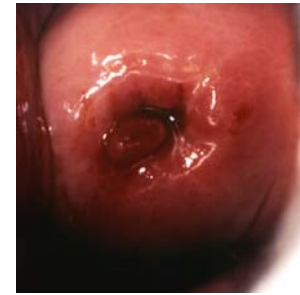Acetowhiting of the mucus on columnar epithelium



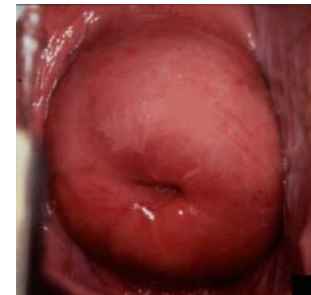Mucus plug



Nabothian cysts

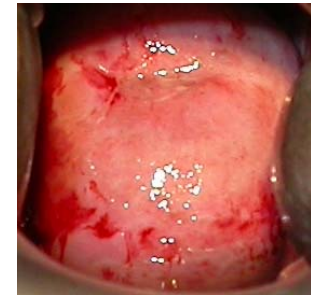
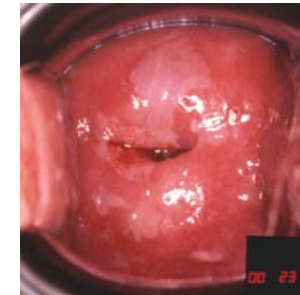
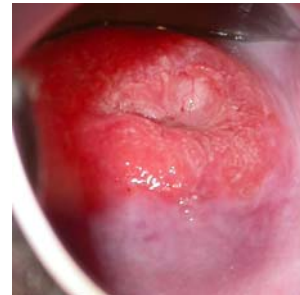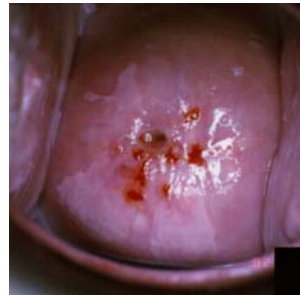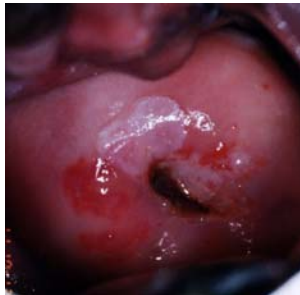


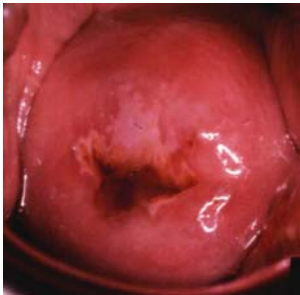Polyp



Acetowhite area far away from SCJ

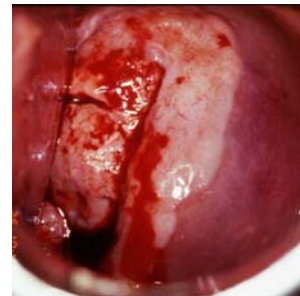
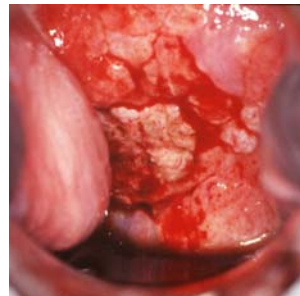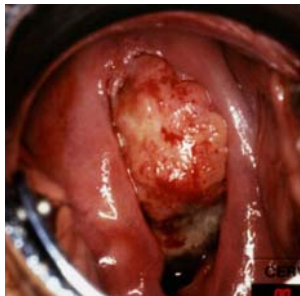
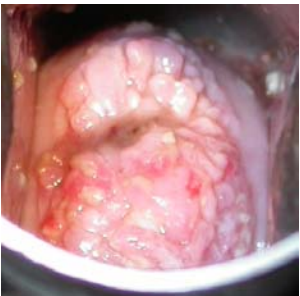
VIA POSITIVE



Well-defined, acetowhite lesions touching the SCJ or close to the os

Acetowhiteness on the entire cervix

CANCER



Acetowhiting of growth on the cervix

Acetowhiting of growth on the cervix; partly obliterated by bleeding

SCJ: Squamocolumnar junction

Source: R. Sankaranarayanan, Ramani S. Wesley. A practical manual on visual screening for cervical neoplasia (IARC technical publication No 41) Available from: press@iarc.fr (IARC Press)

